

## DRESS syndrome related to phenobarbital use – Case report and literature review

Rafael Batista João\*; Alessandra Silveira Colombi; Crish Tatiana Coca Suaznbar; Cândice Marques Mariah Mazzarollo; Thaissa de Medeiros Bruni da Silva; Guilherme de Faria Pinheiro; Charles Name de Dominicis

\***Rafael Batista João**

Department of Neurology, Hospital Municipal Doutor José de Carvalho Florence, Rua Saigiro Nakamura 800, 12220-280, São José dos Campos – SP, Brazil  
Phone: +55 98157 4101; Email: Rafjoao@hotmail.com

### Abstract

DRESS syndrome is a rare clinical condition, usually severe, characterized by skin rash associated with fever, lymphadenopathy and systemic implication. Many drugs are considered triggering factors of DRESS syndrome and, among these, the aromatic antiepileptic drugs stand out as the main cause. Such clinical condition presents a high morbidity rate, which explains the importance of its rapid recognition. The present article has the objective of relating a case in which were noted compatible clinical and laboratory characteristics to this syndrome after the use of phenobarbital, as well as exposing relevant data from recent literature.

### Keywords

dress; skin rash; phenobarbital; antiepileptic drugs; drug reactions

### Introduction

DRESS Syndrome (Drug Rash with Eosinophilia and Systemic Symptoms) is a rare clinical condition characterized by severe skin rash, fever, involvement of internal organs, eosinophilia and/or atypical lymphocytosis. Many factors are considered as triggering, as the use of certain drugs as antiepileptics, hypouricemiant medications, antibiotics and antipsychotics [1]. This report describes a case that led our medical staff to the discussion of several differential diagnoses and demonstrate a clinical situation in which a second-line antiepileptic drug was effective in controlling seizures.

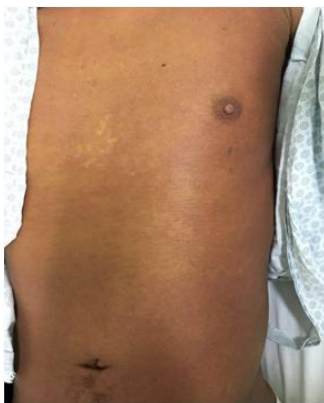### Case Report

Male patient, 32 years old, referred, 15 days before hospitalization, emergence of an insidious pruriginous and non-desquamative maculo-papular exanthema on anterior side of chest and on right forearm, jaundice of skin and mucosae, associated with asthenia, myalgia, fever (without measurement), rhinorrhea and complains of dark urine and white colored feces. Approximately 24 hours after the beginning of clinical manifestations, there was an extension of the skin lesion to entire body surface, with greater involvement of chest and limbs. The patient reported that the manifestations followed a similar pattern, including daily fever, and that it got worse on the next days. Two days before hospitalization,

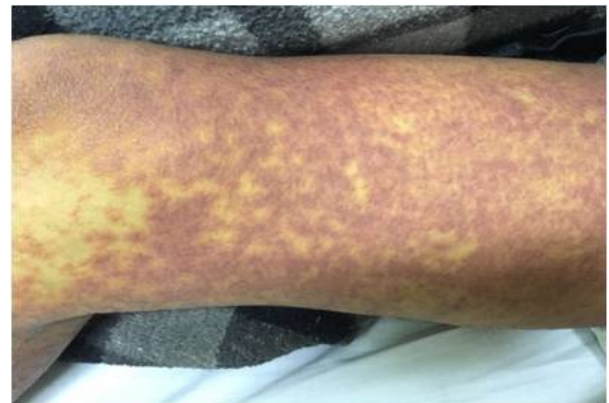
there was complain about moderate intensity cramps at right hypochondrium. At admission, he mentioned being a social drinker and denied smoking or using illicit drugs. When questioned about his pathologic history, he referred recent use of phenobarbital 100mg/day 4 weeks before, after diagnose of epilepsy. Clinical exam showed he was lucid and well-oriented, presenting extensive skin rash, erythema and desquamation of face, chest (Figure 1), abdomen and upper and lower limbs (Figure 2). There was also desquamation of lip mucous, without lesion on oral mucous or conjunctival suffusion; jaundice 3+/4+, cervical and axillary bilateral palpable nodes, with inflammatory aspect and approximate size of 1 to 2 centimeters; normal cardio respiratory exam; abdomen was flaccid, peristaltic, with pain during palpation of right hypochondrium, negative Murphy's sign and palpable liver and spleen; normal osteo- locomotor exam.

Still using the antiepileptic drug, he evolved with worsening of the clinical manifestations and fever after two days of hospitalization. The complementary exams (Table 1) showed significant eosinophilia and progressive decline of hepatic functions. On the third day, the phenobarbital was suspended and he was put on corticotherapy (Hydrocortisone 100mg IV 2 times daily during 10 days). There was a significant improvement of the clinical state on the following days (Figures 3, 4).

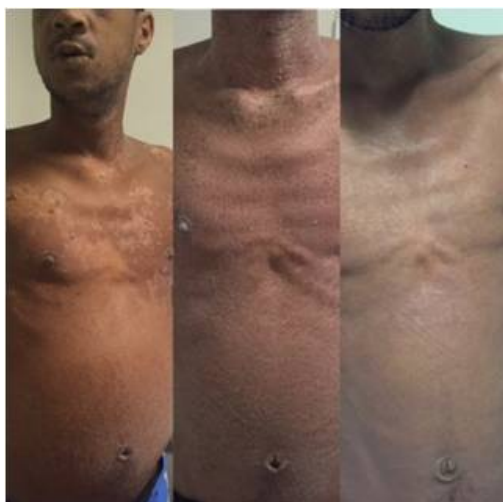## Figures



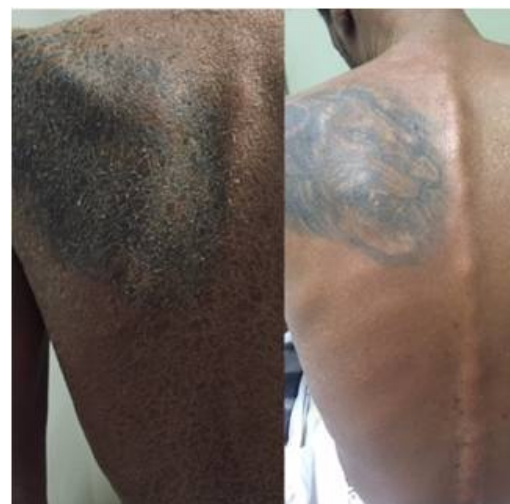**Figure 1:** Thoracic and abdominal morbilliform maculopapular rash.



**Figure 2:** Lower Limb morbilliform maculopapular rash.



**Figure 3:** Morbilliform maculopapular rash with disseminated distribution, with erythema and desquamation in cranio-caudal progression.



**Figure 4:** Skin lesions on scaling in the resolution phase after removal of triggering medication and introduction of corticosteroids.

After hospital release, he was followed by the neurology staff, using gabapentin 400mg three times a day, which completely controlled epileptic seizures for three months. Until this date, there was no adverse reaction to this therapeutic option.

Table 1

Complementary Exams	Day 1	Day 4	Day 6	Day 12	Day 17	Day 26	Outpatient follow-up
Leukocytes (/mm <sup>3</sup> )	12760	18900	20230	12300	9537		
Bastonets (/mm <sup>3</sup> )	638 (5%)	1512 (8%)	200,3 (1%)	123 (1%)	95,37 (1%)		
Eosinophils (/mm <sup>3</sup> )	893 (7%)	189 (1%)	801,2 (4%)	615 (5%)	381,4 (4%)		
Lymphocytes (/mm <sup>3</sup> )	3700 (29%)	3591 (19%)	9508 (47%)	4059 (33%)	2956 (31%)		
AST (U/l)	242		383	422	78	69	
ALT (U/l)	421		411	535	143	132	
Alkaline Phosphatase (U/l)	786				1196	916	
Gama GT (U/l)	883			1139	1325	899	
Total Bilirubin(mg/dl)	6,9	7,2	12,4	25,5	15,4	5,9	
Direct Bilirubin (mg/dl)	5,8	6,2	10,8	23,5	13,9	5	
Indirect Bilirubin (mg/dl)	1,1	1	1,6	2	1,5	0,9	
Urea (mg/dl)	13,6	26,8	25,2	20,7	17,4		
Creatinine (mg/dL)	0,6	0,5	0,5	0,5	0,5		
INR		2,17		0,95	0,92		
CPK (U/L)	228		316				
LDH (U/L)		1447					
Hemocultures (two sets)	Negatives						
Leptospirosis IgM		Reactive (1,3 IU/ml)					
Leptospirosis IgG							Non-Reactive
Microscopic Agglutination Test		Non-Reactive					
EBV serum PCR		Non-Reactive					
HbsAg		Non-Reactive					
Anti-HBs		Reactive					
Anti-HCV		Non-Reactive					
Dengue IgM		Non-Reactive					
Cerebrospinal Fluid		Normal					

## Discussion

Described in 1936, the Hypersensitivity Syndrome was initially attributed to the use of only antiepileptic drugs (AEDs) [2]. Later, there were case reports of patients with similar manifestations to other drugs. In 1996, a new name was proposed, establishing the DRESS Syndrome (Drug Rash with Eosinophilia and Systemic Symptoms), which consists of a group of peculiar clinical manifestations to an unusual adverse reaction to certain drugs [3,4,5], with fatality potential (mortality of about 10%) due to its severe skin and multi-visceral involvement [6,7].

It is estimated that occurs one case of DRESS Syndrome in 10,000 exposures. The onset of signs and symptoms is usually 2 to 6 weeks after initiation of drug use, mostly aromatic antiepileptic drugs (carbamazepine, phenytoin, phenobarbital, lamotrigine), allopurinol and sulphonamide [1,6,7], however, according to recent literature, about 50 drugs can be considered as triggering factors [8] and, in about 10 to 20% of cases, the responsible drug is not identified [9,10,11,12].

Concerning AEDs, the occurrence of DRESS Syndrome is one case to 5,000 exposures to the aromatics class and the reactions are greater in black patients [10]. Non-aromatic AEDs (valproate, gabapentin, topiramate, levetiracetam, tiagabine) are apparently safe. It is worthy to note that certain medication interactions can induce the onset of this syndrome, for example, the simultaneous use of Lamotrigine and Valproate, when occurs increase in the half-life of the Lamotrigine for the inhibitory effect of the Valproate over cytochrome P450 [13].

About the physiopathological basis, studies have shown late immune-mediated hypersensitivity reaction of lymphocytes T activity. In literature there are reports about genetic factors involving the presence of alleles of human leukocyte antigen [6,7,10] and also findings about the susceptibility of certain individuals (slow acetylators) to accumulate toxic metabolites that trigger the immune response [14]. This is an important hypothesis in the cases induced by antiepileptic drugs or sulphonamides, in which hydrolase epoxide deficiency would be directly linked to such mechanisms [15].

When considering infectious factors, it's known that the reactivation of Cytomegalovirus, Epstein-Barr and Human Herpes Virus can also be involved [6,7,10]. Recent studies suggest that the reactivation or first infection by Herpes Virus 6 can also contribute to the onset of the DRESS Syndrome [16,17], due to its capacity of altering the function of the enzymes responsible for detoxification [4].

Clinical findings are usually characterized by fever and morbilliform maculo-papular exanthema, as well as secondary vesicles or blisters at skin edema, areas of skin infiltration, follicular and non-follicular pustules [18]. The first affected areas are face, chest and upper limbs, but later the lower limbs can be involved. The skin rash can become purpuric, especially in distal lower limbs [19], occurring desquamation [13]. In some cases, there is facial edema in periorbital areas [20]. It is worth to mention that it is uncommon for the DRESS Syndrome to involve cutaneous displacement, for it is usually the restricted involvement of mucosa [21]. These characteristics help differentiate between Steven-Johnson or Lyell Syndrome [20].

The systemic involvement is varied. Lymphadenopathy (70% of patients) and hepatopathy (50 to 60% of patients) are the most frequent, this last one being the main cause of mortality [10]. Other complications can be: interstitial pneumonitis [22], nephropathy and myocarditis (can occur in the

beginning or up to 40 days after onset of the disease). Meningoencephalitis can occur about 2 to 4 weeks after drug reaction [23].

The RegiSCAR criteria can be helpful as an evaluation tool. This criteria consider certain inclusion factors (Table 2) for the classification of the probability of DRESS Syndrome as: absent, possible, probable and definite [24].

**Table 2**

RegiSCAR Criteria
Hospitalization
Suspected reaction to related drug
Skin Rash
Fever over 38 °C
Enlargement of lymph nodes in at least two sites
Involvement of at least one internal organ
Abnormalities in blood count:
Lymphocytosis over or under lab limits
Eosinophilia over lab limits (percentage or absolute number)
Platelets under lab limits

*Note: Adapted table version - Kardaun et al. 2007 [24].*

The treatment consists in discontinuation of the triggering medication [14] and corticotherapy, which has many dosages in different bibliographic references [25,26]. This combination usually presents favorable results, though it can take weeks to months to achieve such therapeutic response [26].

After resolution of DRESS Syndrome, some patients have increase in production of antibody and/or immune-mediated illnesses, such as Systemic Erythematosus Lupus, Diabetes Mellitus, Hashimoto's Thyroiditis, Enteropathy and Bullous Pemphigoid [23].

We reported the case of a young patient who presented initially multiple diagnostic hypotheses, such as Acute Cholangitis, Viral Hepatitis, Leptospirosis, Mono-like Syndrome, Steven-Johnson Syndrome, Lyell Syndrome, among others. The clinical and laboratorial findings and time of exposure to phenobarbital were compatible to the criteria for DRESS Syndrome (over 5 points on RegiSCAR<sup>24</sup> – Lymphadenopathy > 1cm in more than two sites; Eosinophilia > 700/mm<sup>3</sup>; extent of cutaneous eruption compatible with DRESS syndrome > 50% of body surface; involvement of liver and muscles; negative serologies for HBV, HCV and negative blood culture; absence of confirmation of other possible causes) and caught our attention as a possibility.

Reactive Leptospirosis IgM was a confounding factor in clinical evaluation, however, the absence of consistent epidemiological history, negative microagglutination test and non-reactive Leptospirosis IgG in outpatient follow-up led us to consider the titration value of the Leptospirosis IgM test as a false

positive result. Considering the possibility of DRESS Syndrome, it is worthy to mention the typical pattern of cutaneous eruption and the satisfactory therapeutic response after discontinuation of the triggering drug and initiation of corticotherapy. In addition, we noted satisfactory control of the epileptic seizures with the use of gabapentin the last months.

## References

1. Lobo I, Ferreira M, Velho G, Sanches M, Selores M. Drug rash with eosinophilia and systemic symptoms (DRESS syndrome). *Acta Med Port.* 2008; 21: 367-372.
2. Merrit H, Putnam T. Sodium diphenylhydantoinate in treatment of convulsive disorders: toxic symptoms and their prevention. *Arch Neurol Psychiatry.* 1939; 42: 1053-1058.
3. Saltzstein S, Ackerman L. Lymphadenopathy induced by anticonvulsivant drugs and mimicking clinically and pathologically malignant lymphomas. *Cancer.* 1959; 12: 164-182.
4. Roujeau JC. Clinical heterogeneity of drug hypersensitivity. *Toxicology.* 2005; 209: 123-129.
5. Roujeau JC, Stern RS. Severe adverse cutaneous reactions to drugs. *N Engl J Med.* 1994; 331: 1272-1285.
6. Husain Z, Reddy BY, Schwartz RA. DRESS syndrome: Part I. Clinical perspectives. *J Am Acad Dermatol.* 2013; 68: 693.
7. Husain Z, Reddy BY, Schwartz RA. DRESS syndrome: Part II. Management and therapeutics. *J Am Acad Dermatol.* 2013; 68: 709.
8. Cacoub P, Musette P, Descamps V, Meyer O, Speirs C, Finzi L, et al. The DRESS syndrome: a literature review. *The American journal of medicine.* 2011; 124: 588-597.
9. Cardoso CS, Vieira AM, Oliveira AP. DRESS syndrome: a case report and literature review. *BMJ Case Rep.* 2011.
10. Criado PR, Avancini JM, Criado RFJ, Santi CG. Reação a drogas com eosinofilia e sintomas sistêmicos (DRESS) / Síndrome da hipersensibilidade induzida por drogas (DIHS): revisão dos conceitos atuais. *An Bras Dermatol.* 2012; 87: 435-449.
11. Mardivirin L, Valeyrie-Allanore L, Branlant-Redon E, Beneton N, Jidar K, Barbaud A, et al. Amoxicillin-induced fare in patients with DRESS (Drug Reaction with Eosinophilia and Systemic Symptoms): report of seven cases and demonstration of a direct effect of amoxicillin on Human Herpesvirus 6 replication in vitro. *Eur J Dermatol.* 2010; 20: 68-73.
12. Bauer KA, Brimhall AK, Chang TT. Drug reaction with eosinophilia and systemic symptoms (DRESS) associated with azithromycin in acute Epstein- Barr virus infection. *Pediatr Dermatol.* 2011; 28: 741-743.
13. Ganeva M, Gancheva T, Lazarova R, Troeva J, Baldaranov I, Vassilev I, et al. Carbamazepine-induced drug reaction with eosinophilia and systemic symptoms (DRESS) syndrome: report of four cases and brief review. *Int J Dermatol.* 2008; 47: 853-860.
14. Vaillant L. Drug hypersensitivity syndrome: drug rash with eosinophilia and systemic symptoms (DRESS). *J Dermatol treatm.* 1999; 10: 267-272.
15. Michel F, Navellou JC, Ferraud D, Toussiro E, Wendling D. DRESS syndrome in a patient on sulfasalazine for rheumatoid arthritis. *Revue du rhumatism.* 2005; 72: 92-96.
16. Descamps V, Valance A, Edlinger C, Fillet AM, Grossin M, Lebrun-Vignes B, et al. Association of human herpesvirus 6 infection with drug reaction with eosinophilia and systemic symptoms. *Arch Dermatol.* 2001; 137: 301-304.

17. Bocquet H, Rouejau JC. Lesreactions cutanées sévères induites par les médicaments. Rev Fr Allergol. 1997; 37: 651-669.
18. Ichine M, Kiesch N. DE BELS D: DRESS syndrome associated with HHV-6 reactivation. Eur J Intern Med. 2003; 14: 498-500.
19. Bachot N, Roujeau JC. Differential diagnosis of severe cutaneous drug eruptions. Am J Clin Dermatol. 2003; 4: 561-572.
20. Kumari R, Timshine DK, Thappa DM. Drug Hypersensitivity Syndrome. Indian J Dermatol Venereol Leprol. 2011; 77: 7-15.
21. Wolf R, Orion E, Basheva B, Matz H. Life-threatening acute adverse cutaneous drug reactions. Clin Dermatol. 2005; 23: 171-178.
22. Gentile I, Talamo M, Borgia G. Is the drug-induced hypersensitivity syndrome (DIHS) due to herpesvirus 6 infection or to allergy-mediated viral reactivation? Report of a case and literature review. BMC Infectious Dis. 2010; 10: 49.
23. Kano Y, Ishida T, Hirahara K, Shiohara T. Visceral involvements and long-term sequelae in drug-induced hypersensitivity syndrome. Med Clin N Am. 2010; 94: 743-759.
24. Kardaun SH, Sidoroff A, Valeyrie-Allanore L, Halevy S, Davidovici BB, Mockenhaupt M, et al. Variability in the clinical pattern of cutaneous side-effects of drugs with systemic symptoms: does a DRESS syndrome really exist? Br J Dermatol. 2007; 156: 609-611.
25. Teo L, Tan E. Sulphasalazine-induced DRESS. Singapore Med J. 2006; 47: 237-239.
26. Michel F, Navellou JC, Ferraud D, Toussiroit E, Wendling D. DRESS syndrome in a patient on sulfasalazine for rheumatoid arthritis. Joint Bone Spine. 2005; 72: 82-85.

**Manuscript Information:** Received: April 10, 2018; Accepted: June 11, 2018; Published: June 15, 2018

**Authors Information:** Rafael Batista João<sup>1\*</sup>; Alessandra Silveira Colombi<sup>1</sup>; Crish Tatiana Coca Suaznbar<sup>2</sup>; Cândice Marques Mariah Mazzarollo<sup>2</sup>; Thaissa de Medeiros Bruni da Silva<sup>2</sup>; Guilherme de Faria Pinheiro<sup>1</sup>; Charles Name de Dominicis<sup>2</sup>

<sup>1</sup>Department of Neurology, Hospital Municipal Doutor José de Carvalho Florence, São José dos Campos – SP, Brazil

<sup>2</sup>Department of Internal Medicine, Hospital Municipal Doutor José de Carvalho Florence, São José dos Campos – SP, Brazil

**Citation:** João RB, Colombi AS, Coca Suaznbar CT, Mazzarollo CMM, Bruni da Silva TDM, Pinheiro GDF, Dominicis CN. Dress syndrome related to phenobarbital use – Case report and literature review. Open J Clin Med Case Rep. 2018; 1424.

**Copy right statement:** Content published in the journal follows Creative Commons Attribution License (<http://creativecommons.org/licenses/by/4.0>). © João RB 2018

Journal: Open Journal of Clinical and Medical Case Reports is an international, open access, peer reviewed Journal focusing exclusively on case reports covering all areas of clinical & medical sciences.

Visit the journal website at [www.jclinmedcasereports.com](http://www.jclinmedcasereports.com)

For reprints and other information, contact editorial office at [info@jclinmedcasereports.com](mailto:info@jclinmedcasereports.com)